



Government of **Western Australia**  
North Metropolitan Health Service  
WA Cancer and Palliative Care Network - Clinical Implementation Unit



# Understanding a melanoma pathology report



**WA Kirkbride**  
MELANOMA ADVISORY SERVICE



This pamphlet is designed to help you read your melanoma pathology report.

It contains general information only, and we ask that you speak with your treating doctor about your individual diagnosis. Your doctor can also provide a copy of your report for your own records.

## What is a pathologist?

A pathologist is a doctor who looks closely at tissue taken from your body (under a microscope) to see if the tissue has normal or diseased cells.

## What is a pathology report?

After the doctor performs the biopsy, the tissue is sent to a pathologist. First, the pathologist looks at the tissue with the naked eye to choose areas for a closer look. A tissue block is made by setting this tissue in paraffin wax. The following day thin slices are placed on glass slides and given to the pathologist to look at down the microscope.

The results of the pathologist's examination are included in a pathology report, which is sent to your doctor. It is this report and results that will be discussed at your appointment with your doctor.

## How long does the pathology report take?

A whole report may take up to two weeks to finish. This report has important information about the melanoma, which can help decide the best treatment for you.

## What information will I find on the report?

The report includes a number of easy-to-read sections, including:

- **Clinical details** – refers to where on the body (site) the tissue was taken from and the kind of biopsy method used (eg: excision, incision, shave biopsy, fine needle biopsy).
- **Macroscopic description** – is the pathologist's notes of what the tissue looked like to the naked eye. This section will describe the measurements of the specimen and the measurements of the melanoma.
- **Microscopic description** – This is the most technical part of the report and is the story of what was seen under the microscope. The pathologist will determine a diagnosis once all of the tissue's features are assessed.
- **Conclusion** – A brief summary of what was seen in the tissue and the final diagnosis.



The following is an example of how a synoptic pathology report may look.

<p><b>The Pathology Laboratory</b></p> <p>Patient Name: Smith, Jennifer DOB: 05/01/1961 Requested by: Dr Scott, Susan Requested on: 10/02/2021 Specimen received: 11/02/2021</p>
<p><b>Sample Pathology Report</b></p>
<p><b>CLINICAL DETAILS</b></p> <p>Change in mole right arm</p>
<p><b>MACROSCOPIC</b></p> <p>Ellipse of skin 10x8x5mm with an irregular brown area 5x4mm</p>
<p><b>MICROSCOPIC REPORT</b></p> <p><b>Specimen type:</b> Skin excision <b>Site:</b> Right arm <b>Melanoma subtype/classification:</b> Superficial spreading melanoma <b>Breslow thickness:</b> 0.50 mm <b>Clark level:</b> Level 3 <b>Ulceration:</b> Absent <b>Mitotic rate:</b> 0 per mm<sup>2</sup> <b>Satellite Metastases:</b> Not seen <b>Tumour infiltration by lymphocytes:</b> Present; brisk <b>Regression:</b> Present <b>Lymphovascular invasion:</b> Absent <b>Perineural invasion:</b> Absent <b>Pre-existing lesion:</b> Nil</p>
<p><b>CONCLUSION</b></p> <p>Excisional biopsy skin right leg: superficial spreading malignant melanoma <b>Margins:</b> Deep 4.5mm, Lateral 2mm</p>

## Common terms used in the microscopic description section

### Histological classification/type of melanoma

There are different types of melanoma:

#### Superficial Spreading Melanoma

This is the most common type of melanoma and it may grow on any part of the body; it is more common on the chest and back of men, and on the legs of women.

#### Nodular Melanoma

This is the fastest growing type of melanoma. It looks like a raised bump and can be black, brown, pink or red in colour, or have no colour at all.

#### Lentigo Maligna Melanoma

These grow on the face and sun-exposed areas of the upper body in elderly people. It begins as a large freckle.

#### Acral Lentiginous Melanoma

This is a rare type of melanoma. It tends to grow on the palms of the hand, soles of the feet or under the nails. If the melanoma grows under the nail, it is called subungal. This type of melanoma is most common in darker skinned people.

#### Rare subtypes

There are other less common types of melanoma eg: desmoplastic melanoma. Melanoma can also develop inside the body, such as in the digestive, respiratory and reproductive tracts (Mucosal melanoma) and can develop in the eye (uveal or ocular melanoma). These are very rare.

Note: some melanomas do not always follow the descriptions above and cannot be given a classification. If this is the case, your doctor will discuss what it means to you.

## Breslow Thickness

This is a measure of the melanoma from the very top of the tumour (called the granular layer) to the deepest part of the tumour.

An instrument called an ocular micrometer is used to measure the tumour in millimetres. Thinner melanomas have a better prognosis. The Breslow Thickness is the most important factor in staging, and more important than Clark Level.

Less than 1 mm	Thin
1-4 mm	Intermediate
4.1 mm or thicker	Thick

## Clark Level

The Clark Level is a number that ranges from 1-5 (written in Roman numerals I-V).

This number indicates what layer of the skin the melanoma reaches. It is not like the Breslow Thickness measurement in millimetres.

The higher the Clark Level the deeper into the tissue it extends. Clark Level is not used for staging, as it is not a good predictor of prognosis.

**This number should not be mistaken for the stage of melanoma.**

### The Clark Levels are:

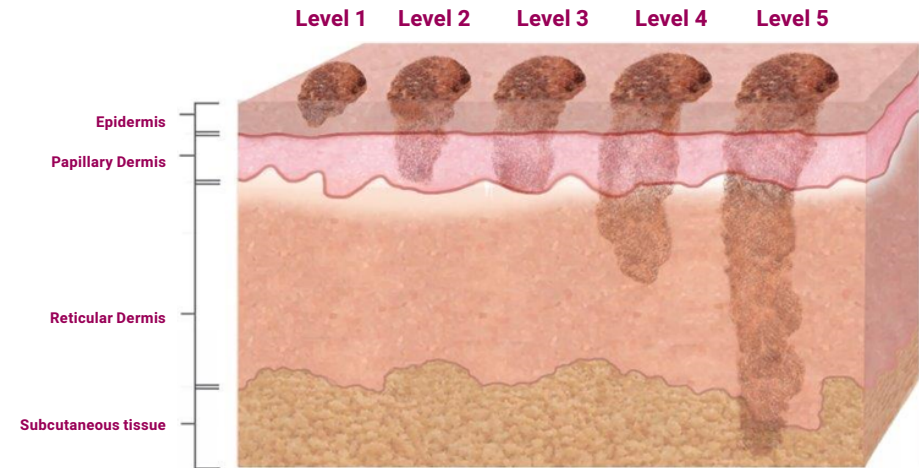
**Clark Level I** – the melanoma is contained in the epidermis (top layer of the skin). This may also be called an in-situ melanoma.

**Clark Level II** – the melanoma goes into the upper dermis (second layer of the skin).

**Clark Level III-IV** – the melanoma grows more deeply in the dermis but is still contained within the skin.

**Clark Level V** – the melanoma goes into the fat beneath the dermis.

## Clark Levels



## Ulceration

Ulceration is the breakdown of the top layer of skin over the melanoma. If present, it can mean rapid tumour growth. The presence or absence of ulceration affects the stage of the melanoma.

## Mitotic rate

This shows how quickly the cells in the melanoma are dividing. A higher score can mean a faster growing melanoma.

The pathologist measures mitotic rate by finding an area of the tissue sample with the most dividing cells (mitoses) and counts the number of mitoses within a square millimetre. This is written as a number per square millimetre (eg: 1/mm<sup>2</sup>).



## **Growth phase**

This refers to a vertical growth phase, which means the cells are growing deeper into the tissues; or a radial growth phase, which means the cells are spreading sideways in the epidermis.

## **Regression**

On the report this is either present or absent. Regression describes an area of inflammation or scar tissue where it looks like melanoma cells have been, but have been destroyed by the body's immune system.

## **Lymphovascular invasion**

On the report this is either present or absent. If it is present, melanoma cells were found in a blood vessel or lymphatic vessel.

## **Margins of excision**

The lateral or side margin explains where the tumour was in relation to the edges of the biopsy. The deep margin describes the amount of normal tissue under the tumour. A positive margin means the tumour is present at the edge, where the tumour was removed. This means more tissue will need to be removed.

## **Tumour Infiltrating Lymphocytes (TILS)**

When the pathologist looks at the melanoma under the microscope, they look for the number of lymphocytes (white blood cells) in the tissue. This is called brisk, non-brisk or absent. If there are TILS, this means the immune system has recognised that the melanoma cells are abnormal and are attacking them.

## **Perineural invasion**

Perineural invasion means cancer that has spread to the space around a nerve. This is rare and is usually only in melanomas on the head and neck area.

## **Microsatellites or Satellites**

A microscopic satellite (microsatellite) is any nest of metastatic tumour cells (cancer that has spread from the primary cancer) which are away from the main body of the tumour. On the report they are present or absent. If present, they increase the risk of melanoma returning in the area or in other parts of the body.

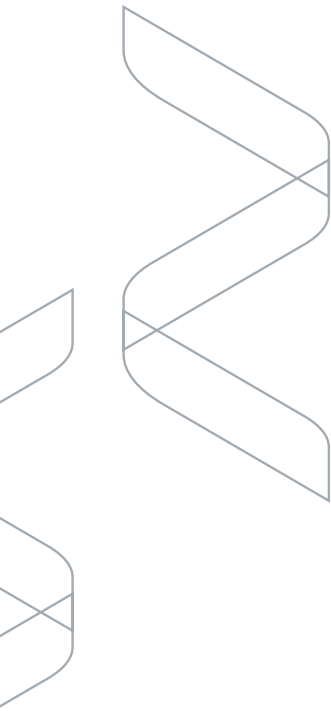## **Pre-existing lesion**

Describes whether the melanoma started in a mole (naevus) already present on the skin. Some melanomas start in an existing mole and some start as a new lesion in normal skin.

## **Molecular testing**


If you have metastatic melanoma, your doctor will talk to you about a BRAF mutation test. BRAF is a protein found in cells which is involved in normal cell growth. An abnormal BRAF protein due to a change (mutation) in the genomic material of cells causes the cells to grow in an uncontrolled way. Approximately 40 per cent of all melanomas have the BRAF mutation. People with metastatic melanoma who have this mutation in their melanoma may benefit from treatment with targeted therapy. This test can usually be done using tissue already removed in previous surgery.





---

## **WA Cancer and Palliative Care Network - Clinical Implementation Unit**

 Queen Elizabeth II Medical Centre. Locked Bag 2012  
Nedlands WA 6009

 (08) 6457 0855  [wacpcn@health.wa.gov.au](mailto:wacpcn@health.wa.gov.au)

This document can be made available in alternative formats on request.

© North Metropolitan Health Service 2021  
Produced by WA Cancer and Palliative Care Network  
– Clinical Implementation Unit